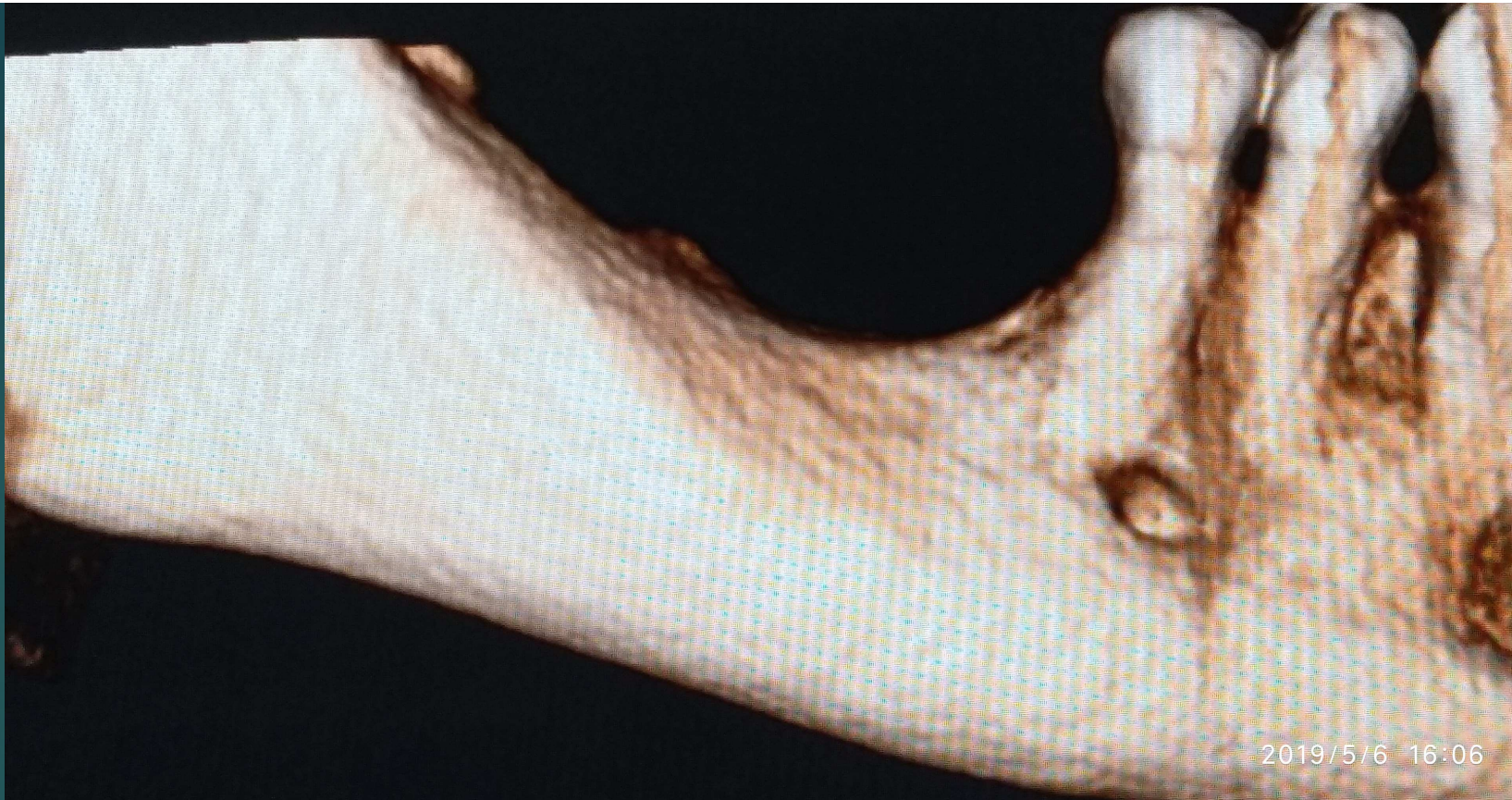
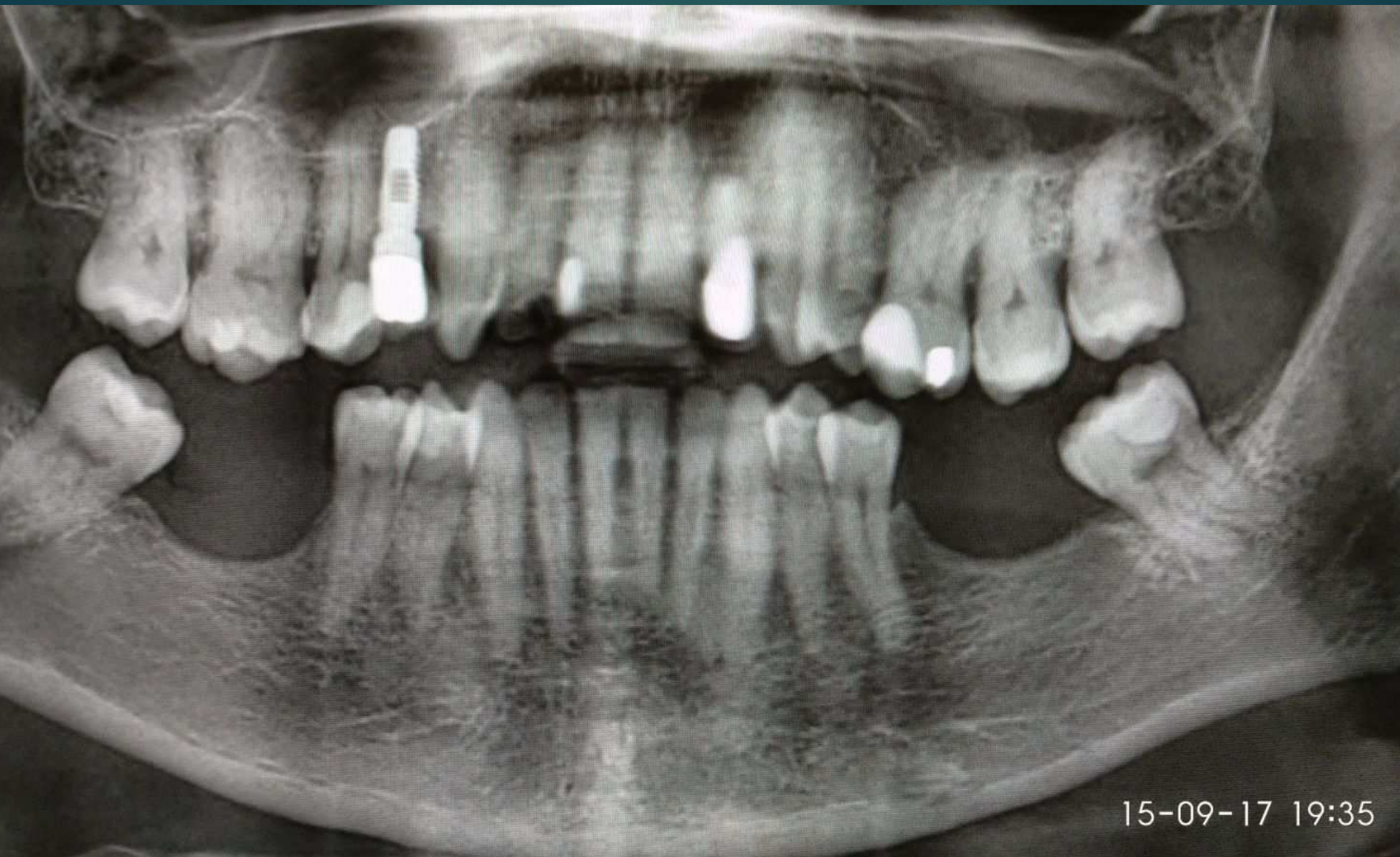


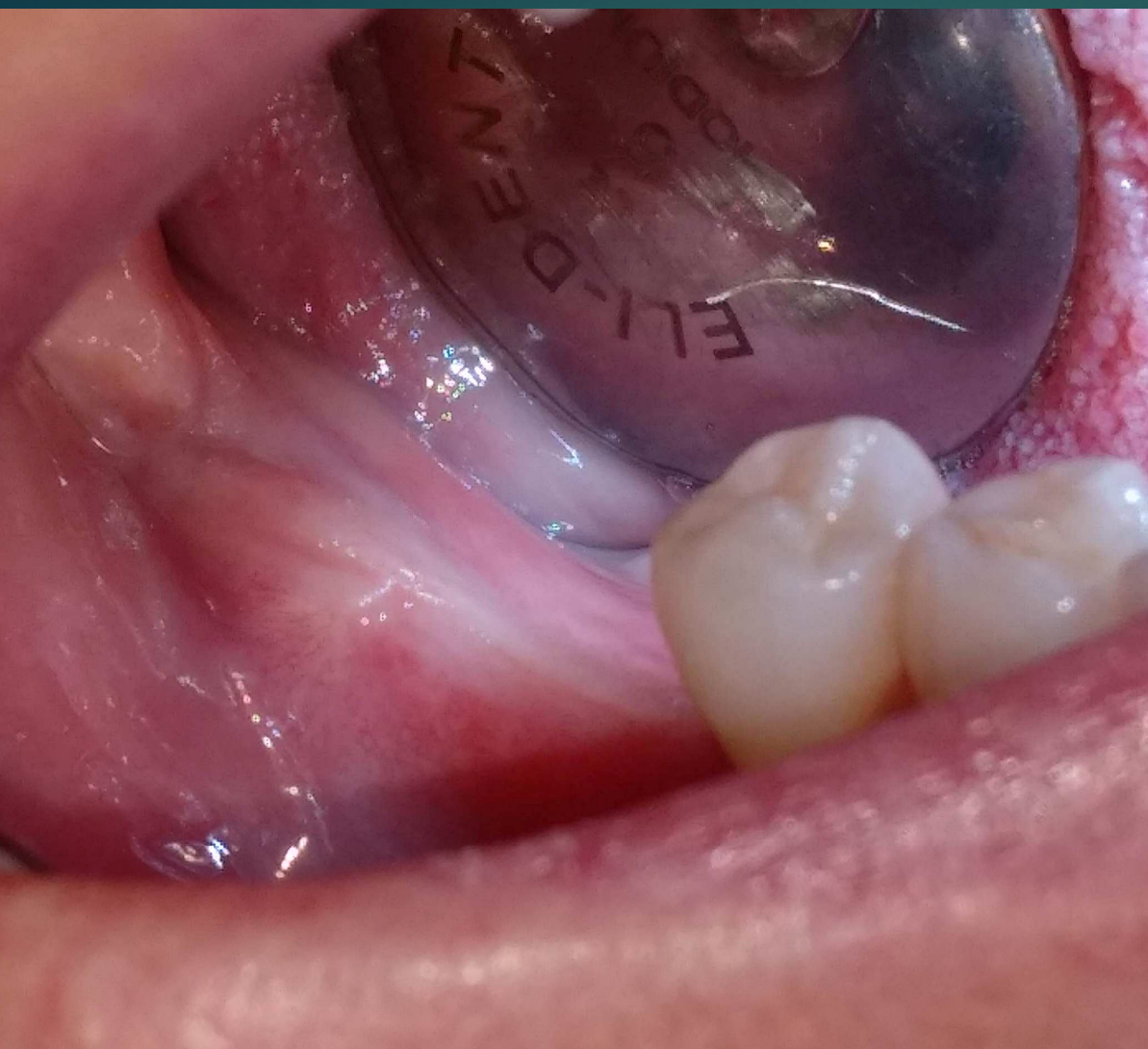GBR mandibola posteriore con Impianti *SHARP*

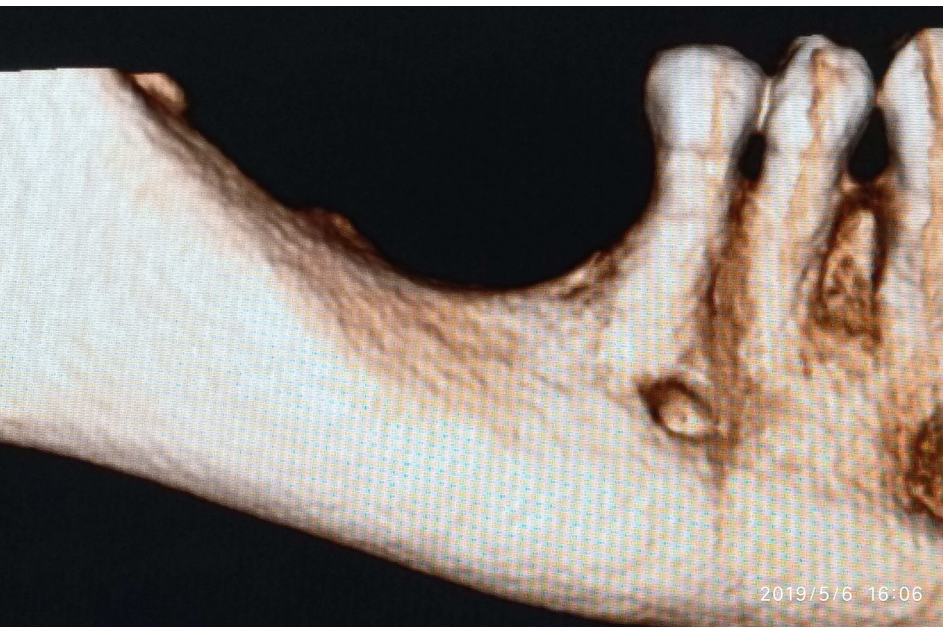IMPLADENT



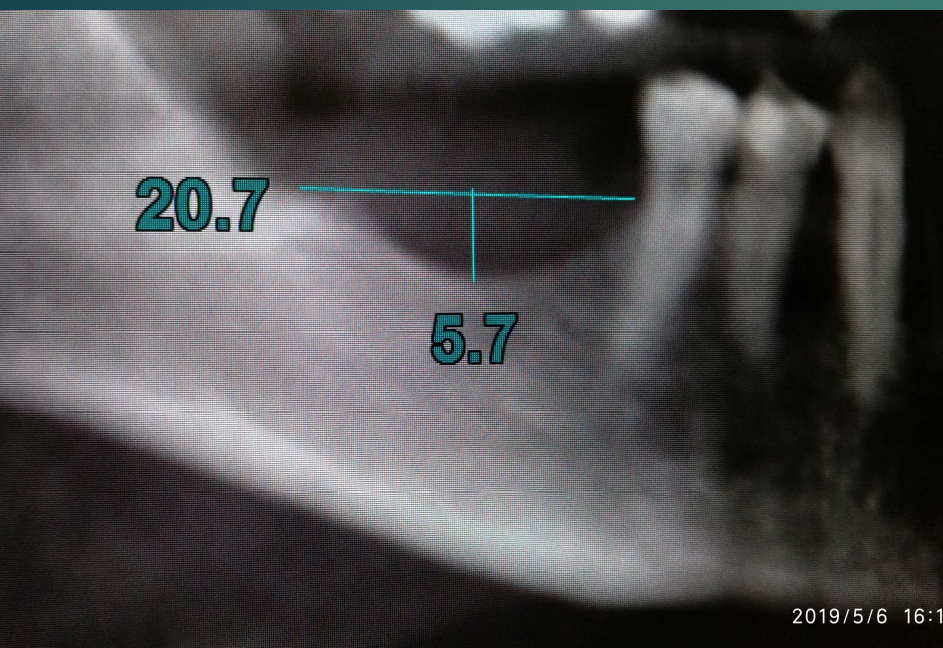
Deficit osseo mandibolare bilaterale da avulsione di primo e secondo molare  
permanente e mesioinclinazione dei terzi molari

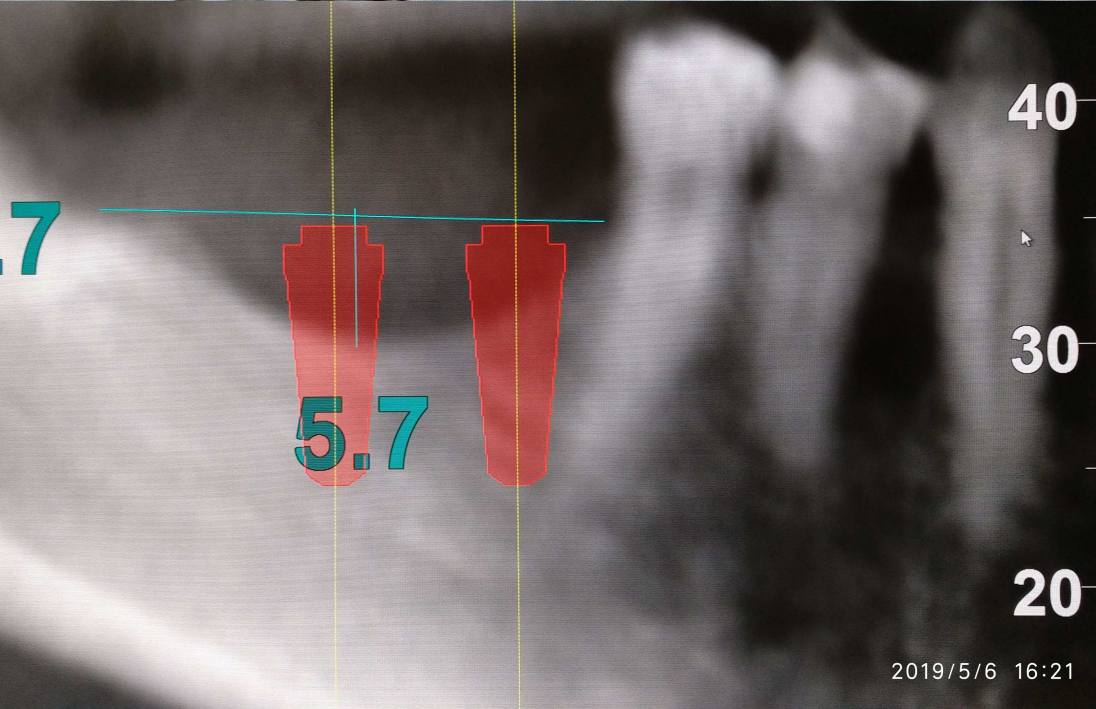
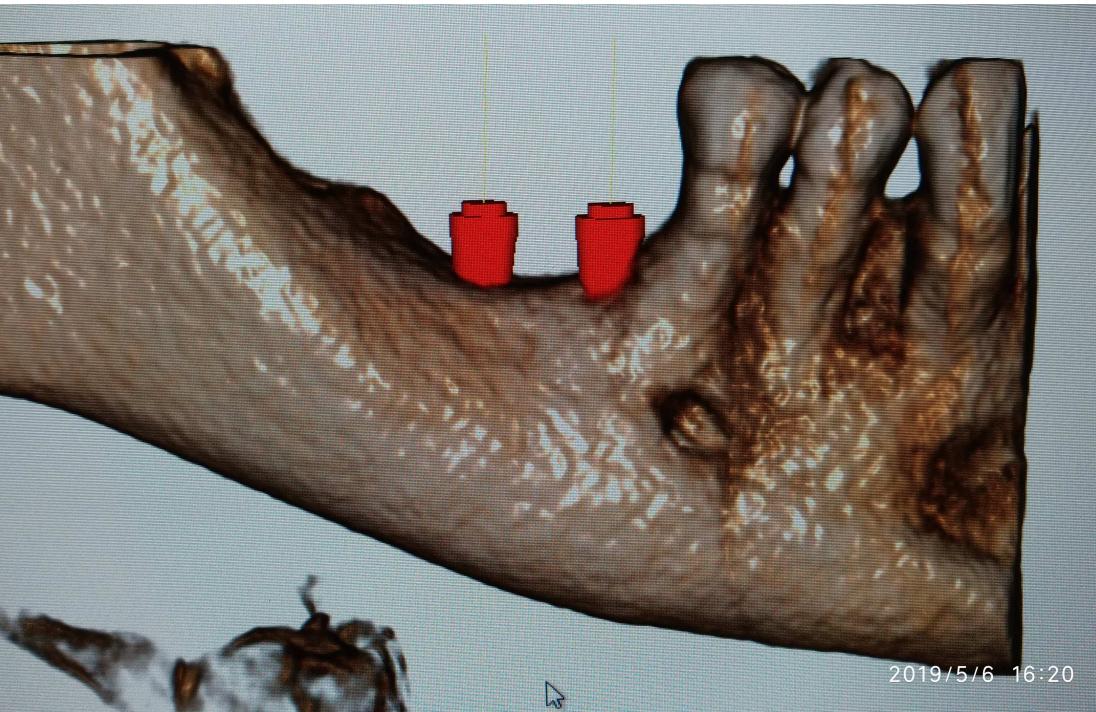


3 mesi dopo l'avulsione del 3° molare: guarigione  
tessuti molli. Atrofia della cresta ossea ed  
recessione del fornice buccale




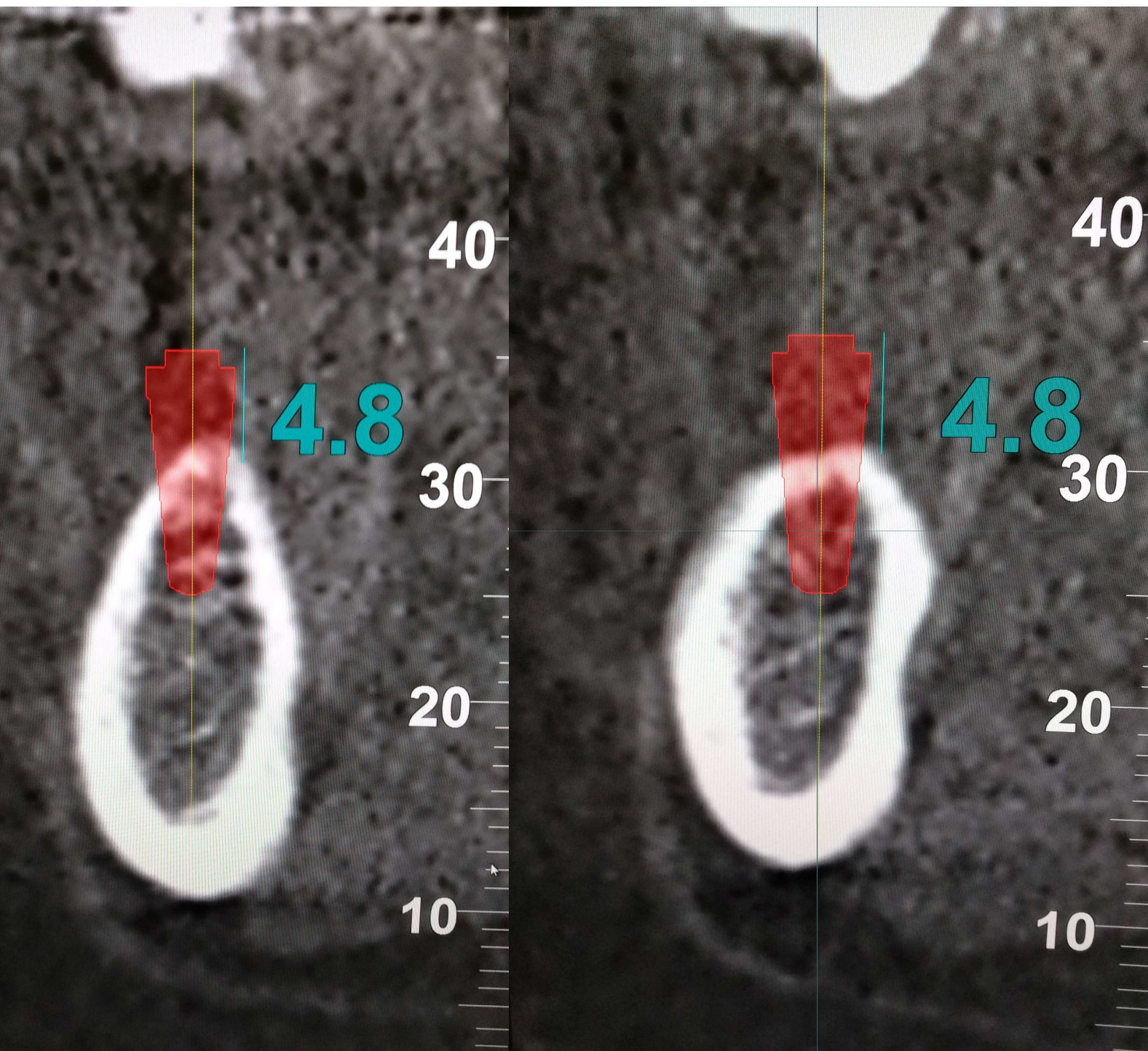
Misurazione del difetto da riempire: circa 6 mm in verticalità/altezza e 21 in lunghezza, mantenendosi 1 mm scostati dall'ultimo dente ed 1 mm al di sotto del picco osseo mesiale





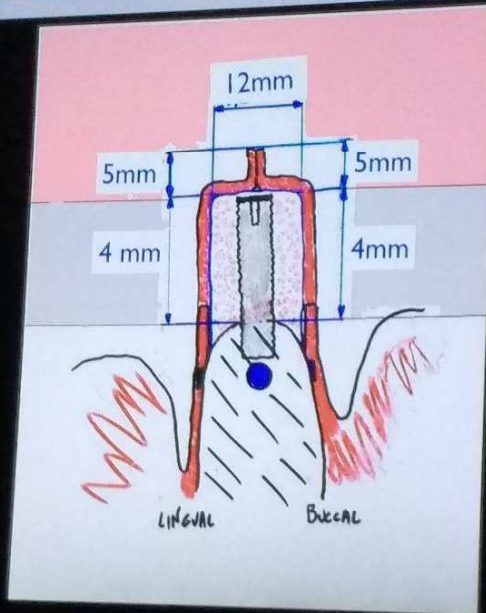
Progetto implantare





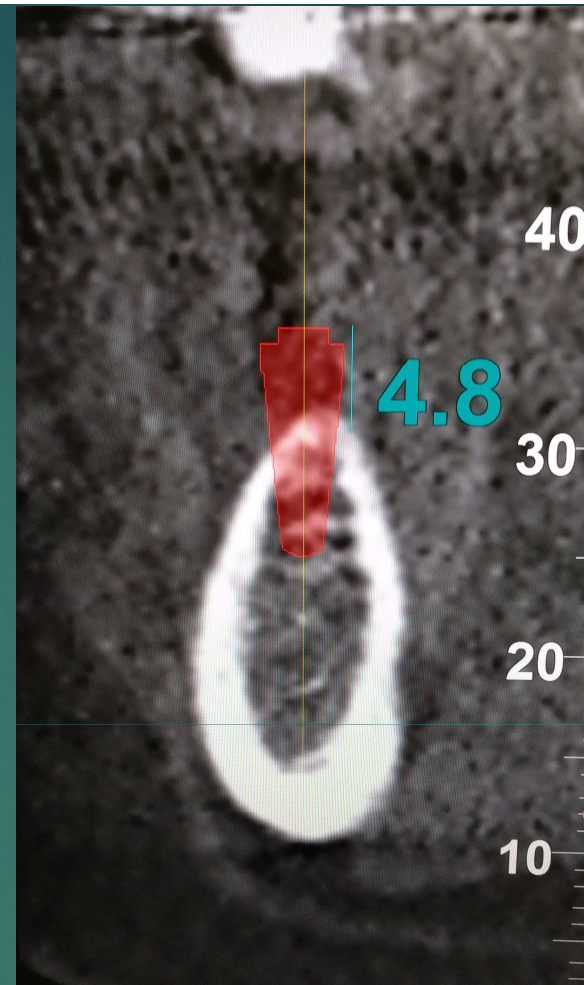
La rigenerazione verticale programmata è di circa 5 per ogni impianto

Quale tipo di rigenerazione ossea verticale potrebbe essere pianificata con 30 mm di lembi avanzati coronalmente???



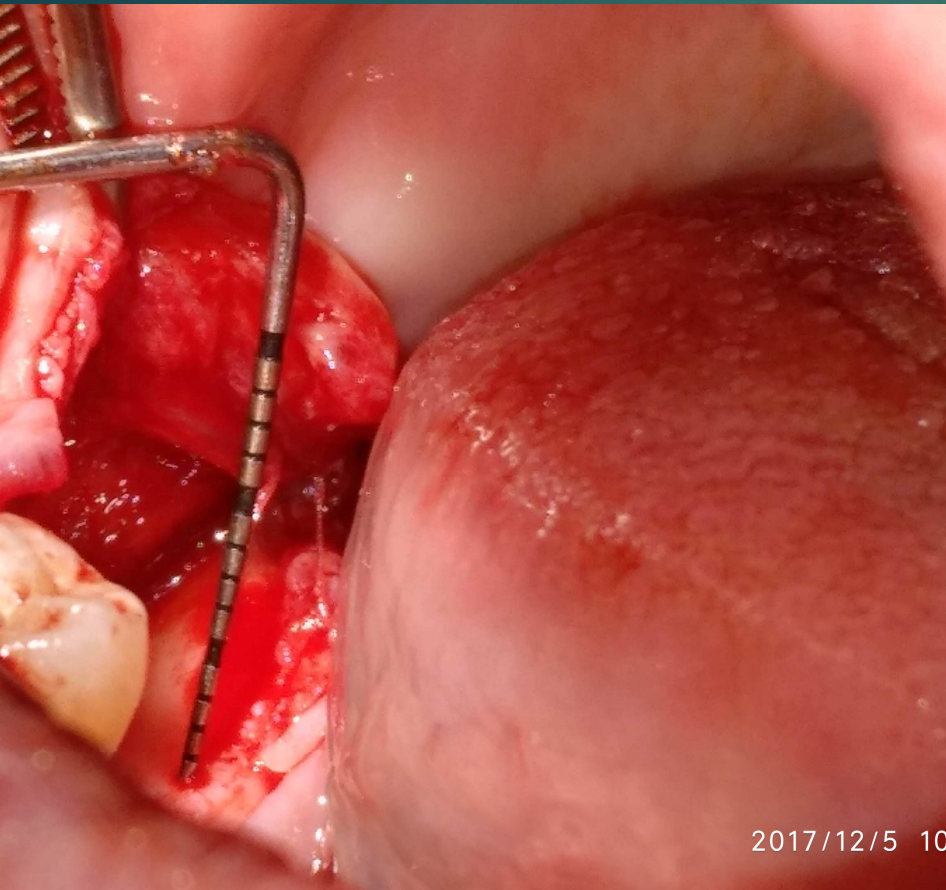
Rispettando le linee guida (suture a materassoio orizzontale e ampia orizzontalità) l'incremento medio potrebbe essere intorno ai 4 mm

Dr. Marco Ronda

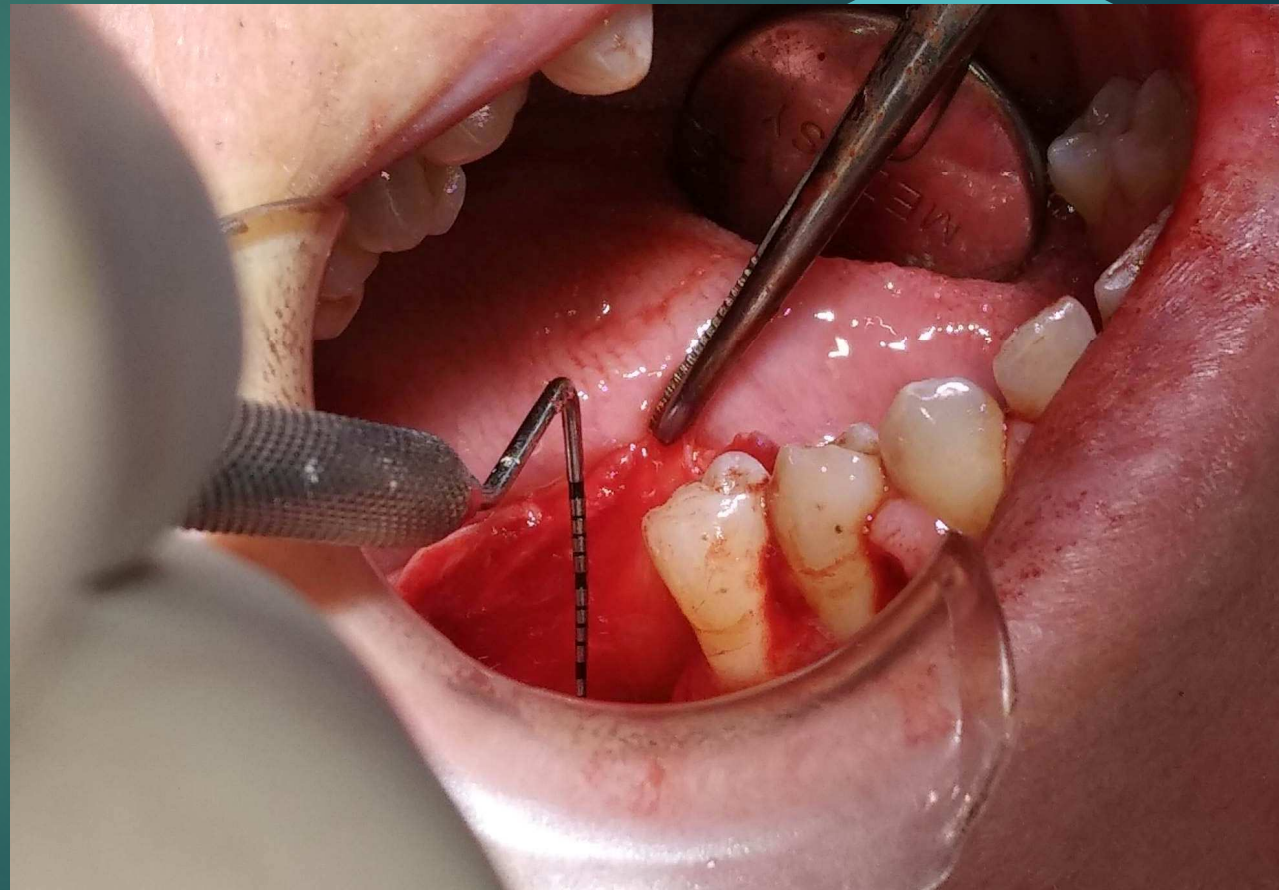


amo due conti: occorreranno almeno 32 mm di lembi avanzati coronalmente

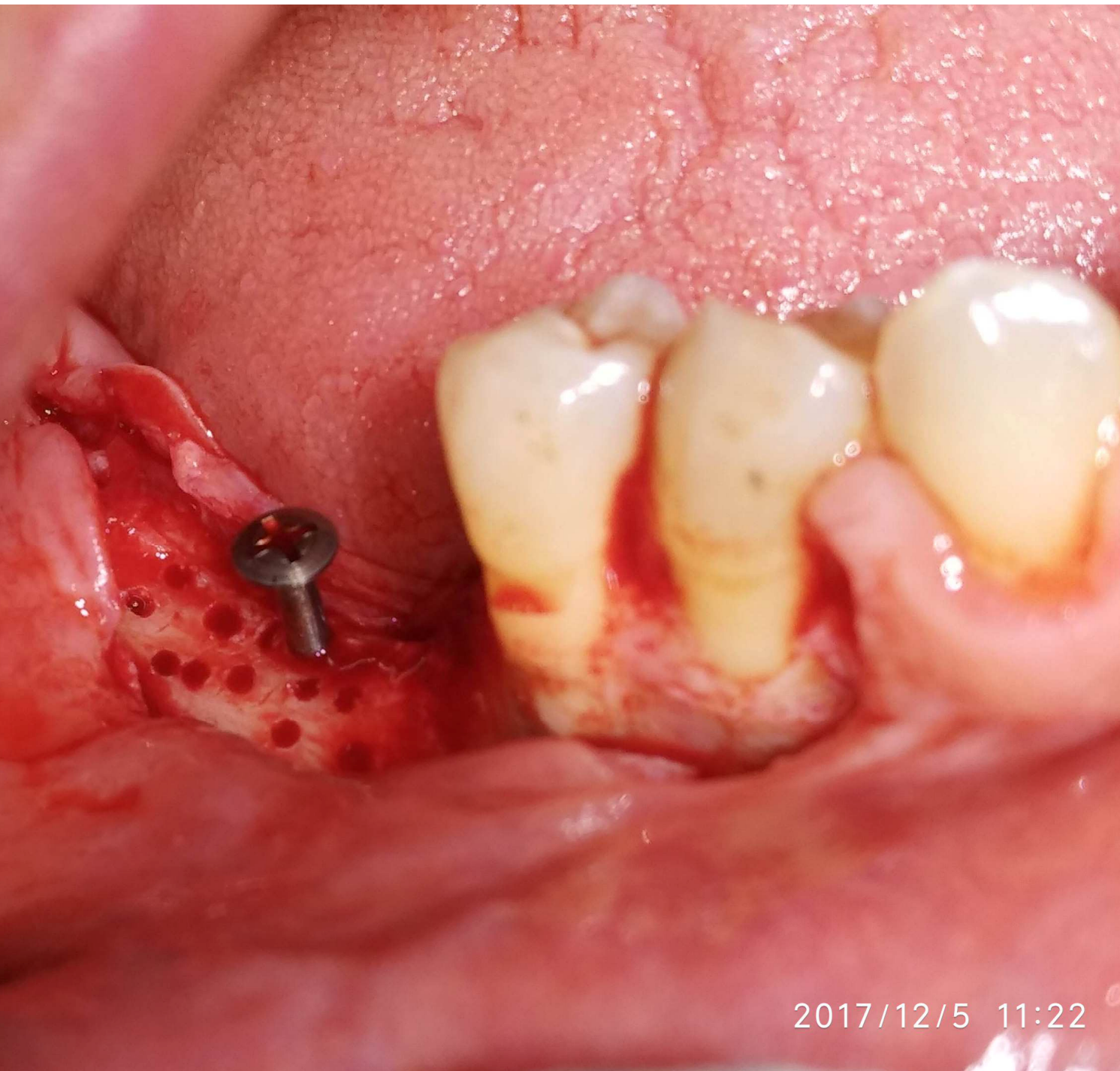
# 1° Fase Chirurgica (T0)



Lembo buccale di 20 mm

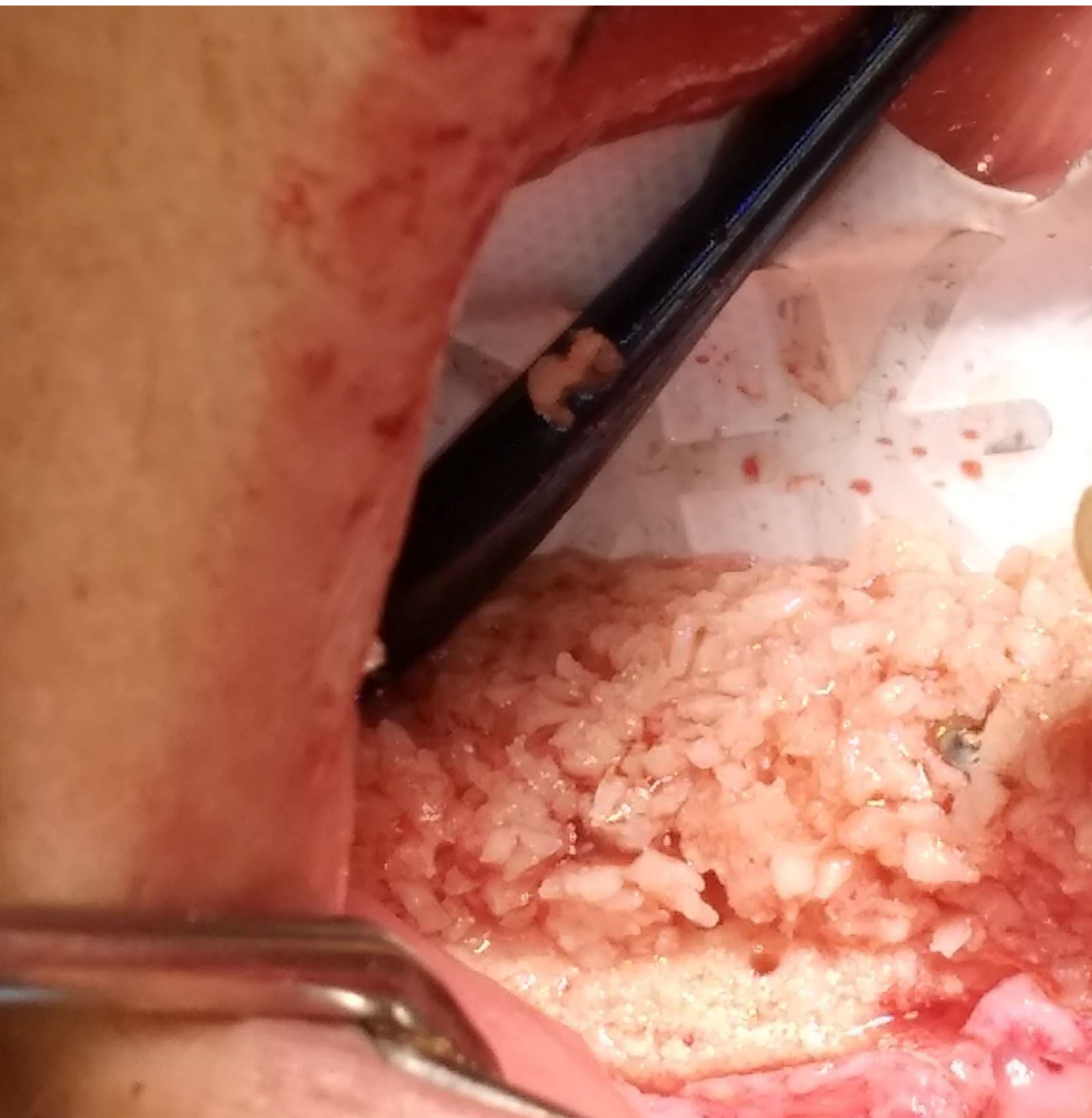


Lembo linguale di 15 mm


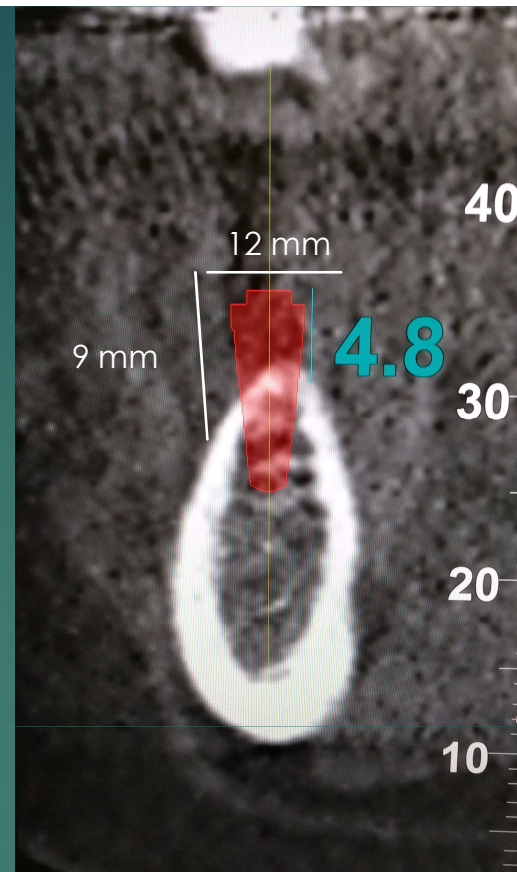
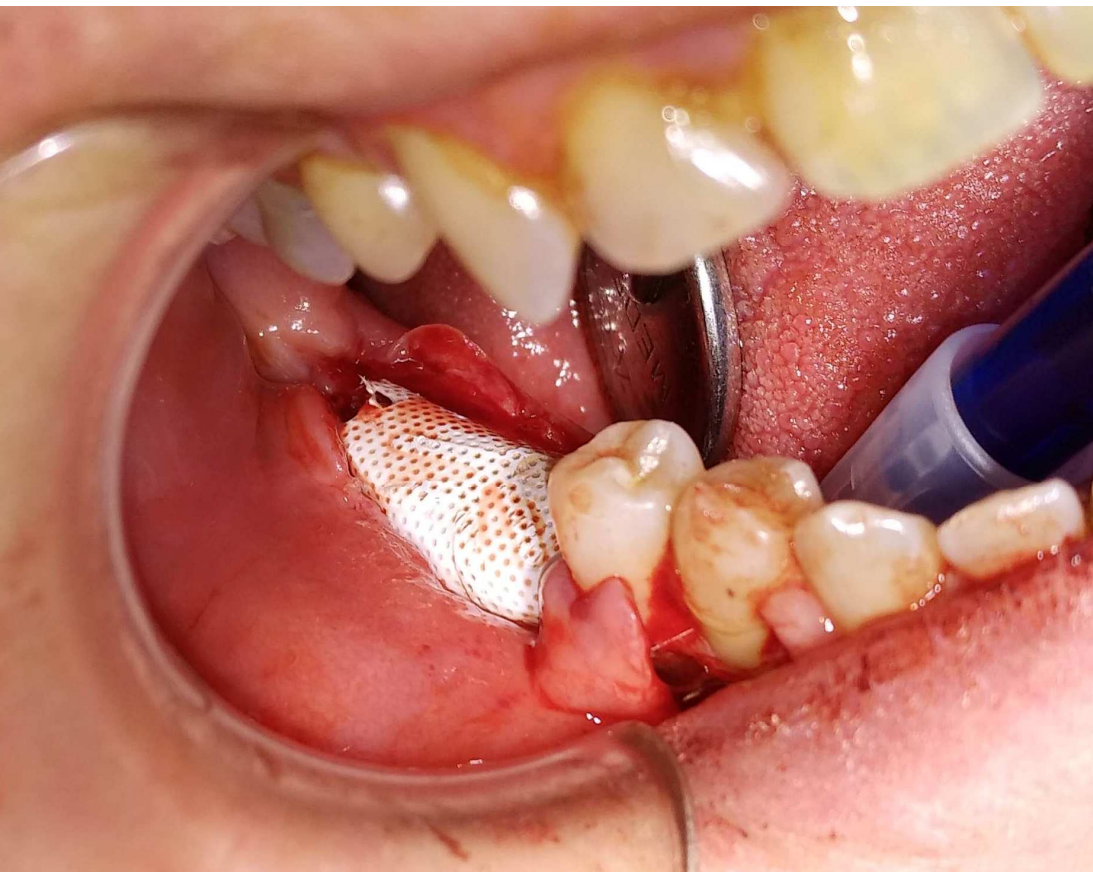


Refresh della corticale con  
'Tenting Screw' sporgente per  
mm. Notare il disegno del lembo  
esteso 2 denti mesialmente al  
difetto da rigenerare.

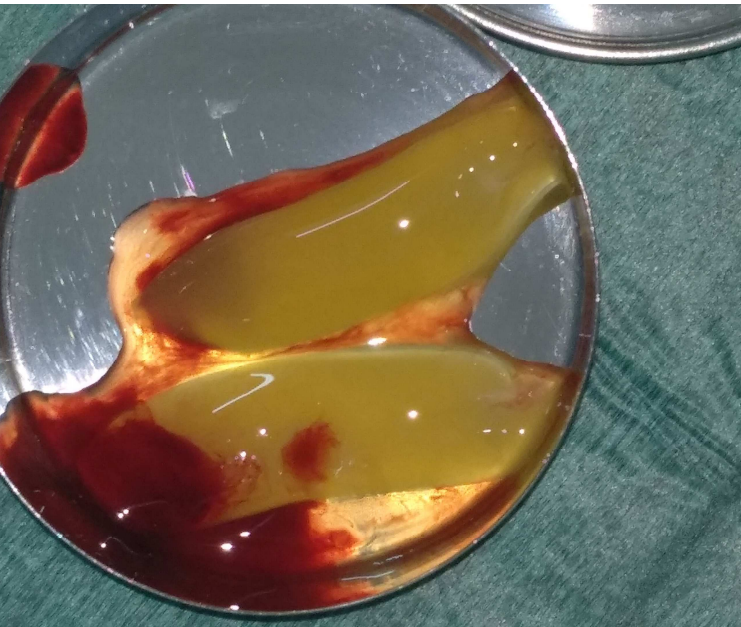2017/12/5 11:22



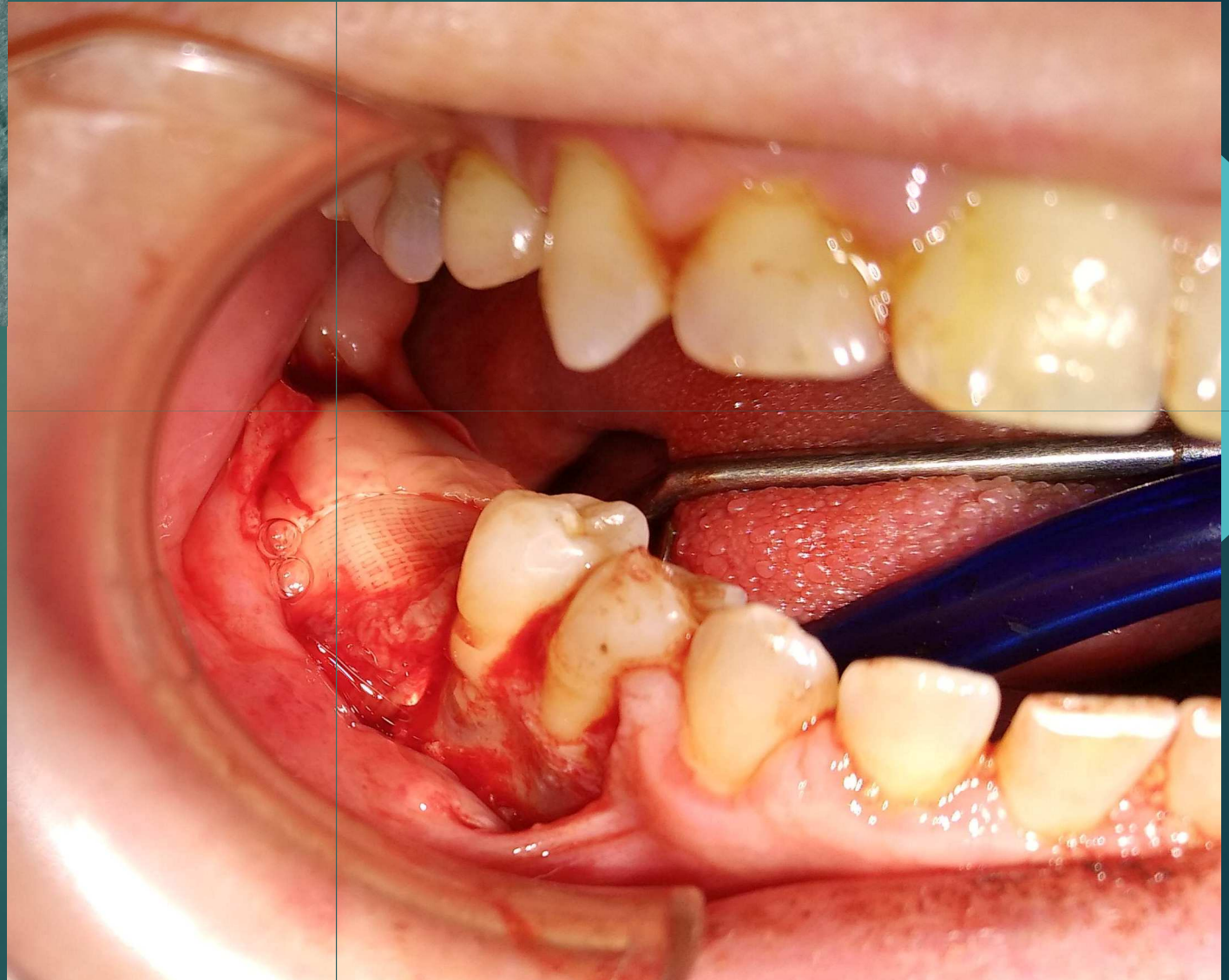
Innesto osseo particolato miscelato  
con LPCGF (Low Phase Concentrated  
Grow Factor) + metronidazolo

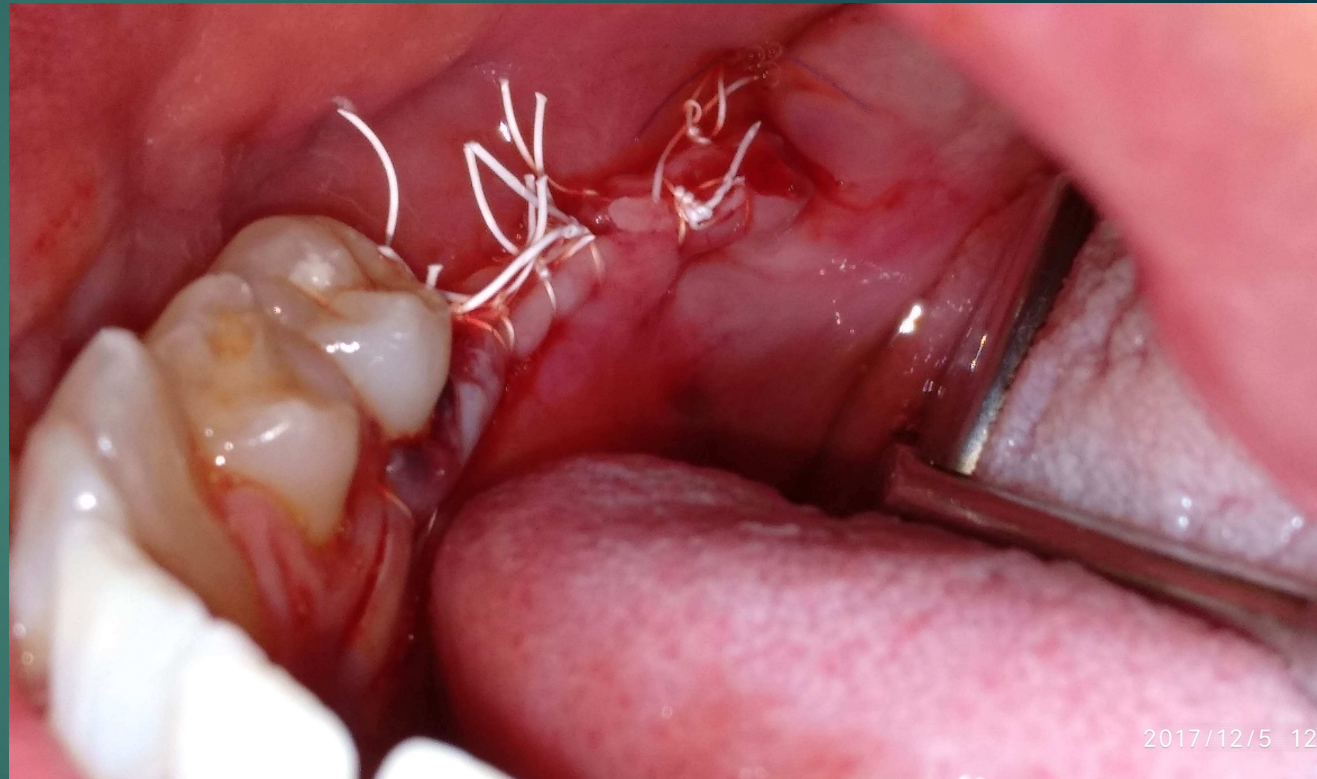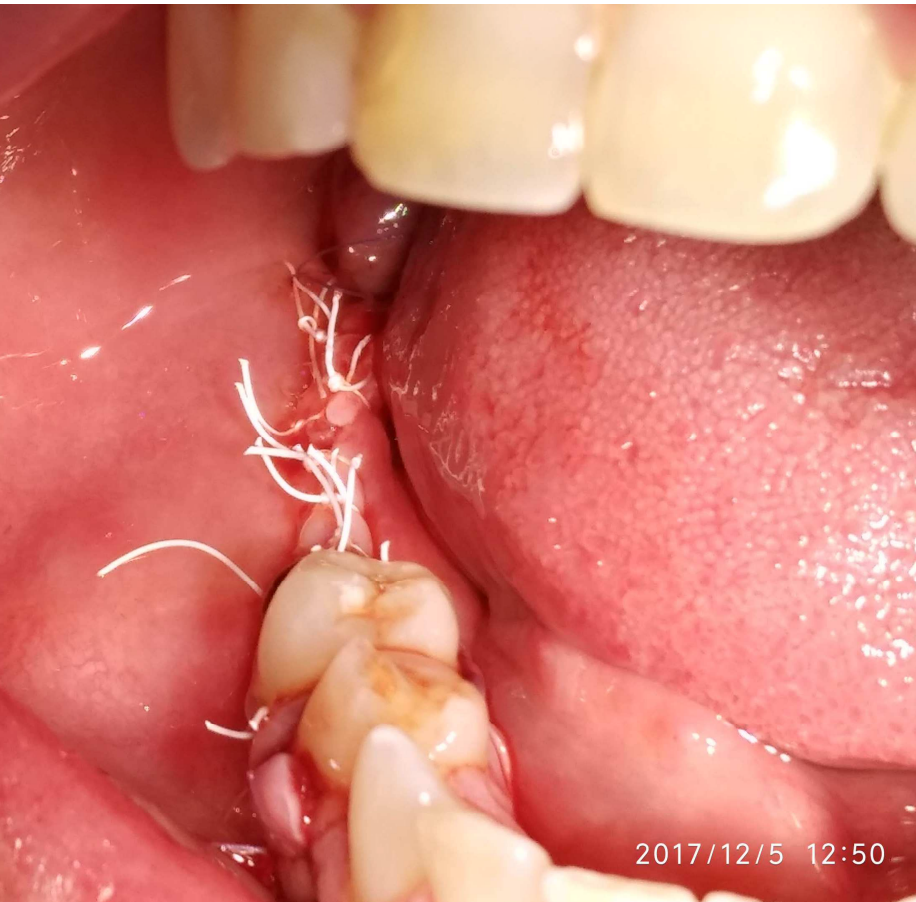


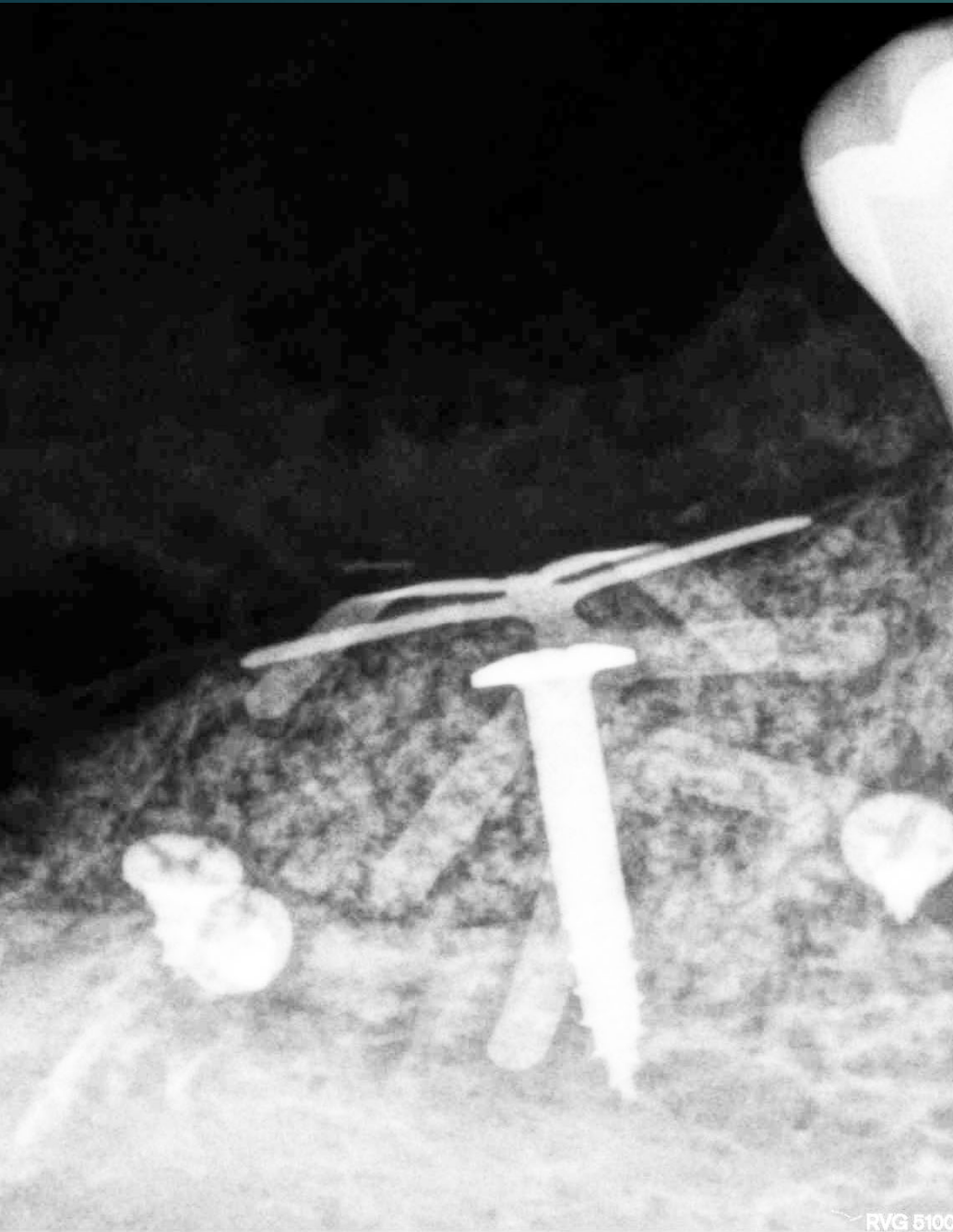
La membrana scelta in PTFE è una 25x30 mm † Cytoplast (mm: 9+9+12)



Membrane in CGF

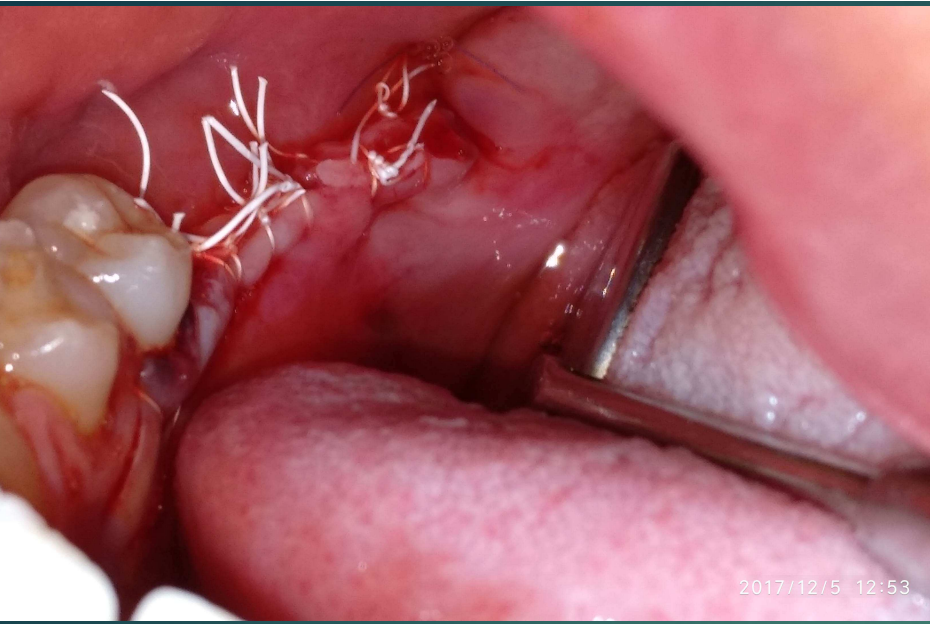




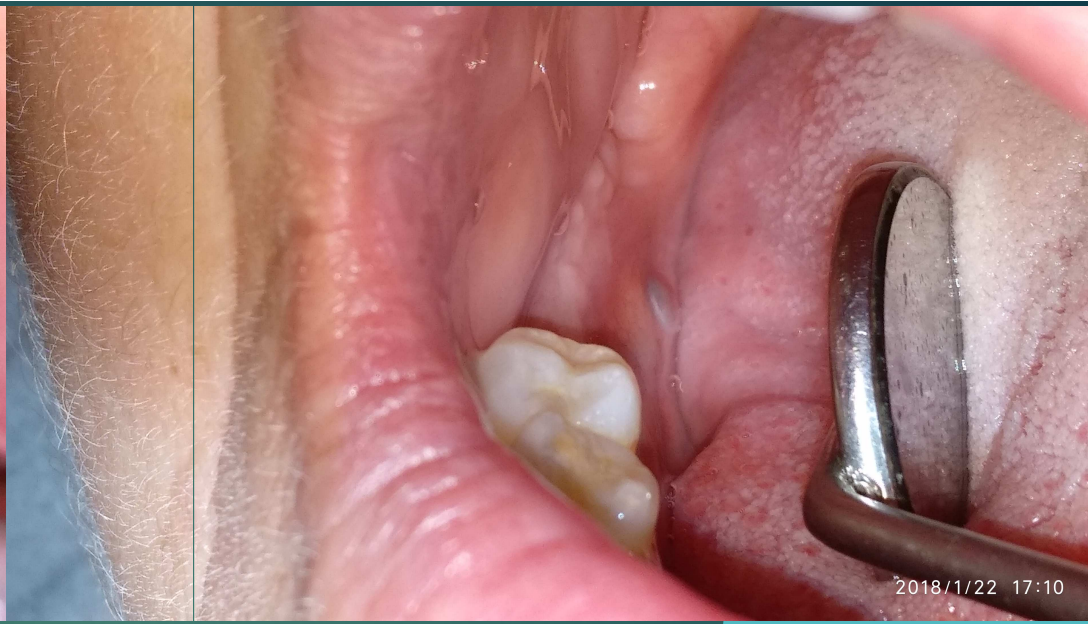

Rx di fine intervento

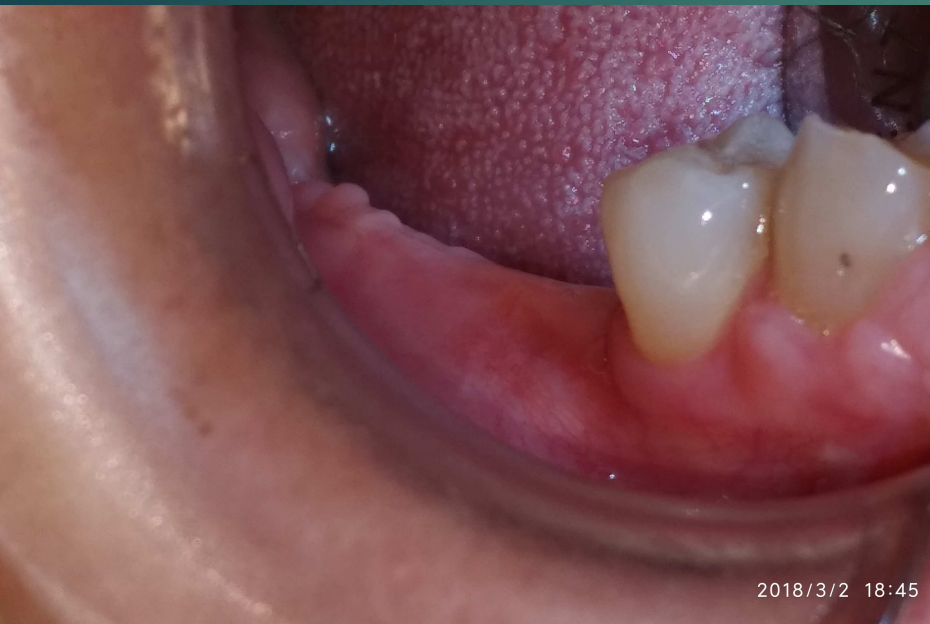



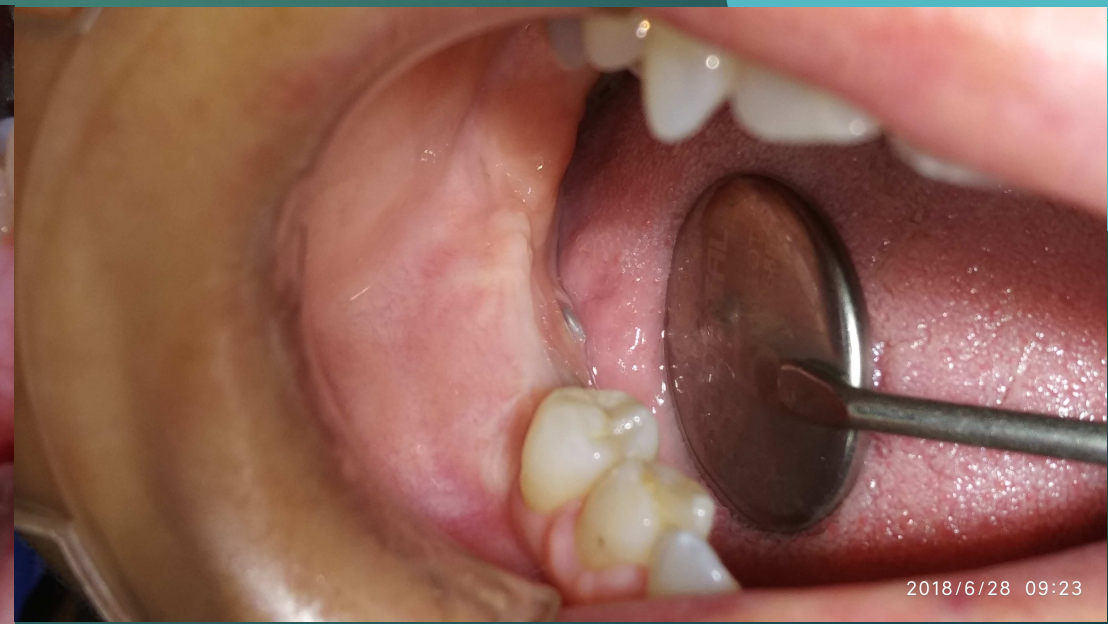Fine intervento



1 mese

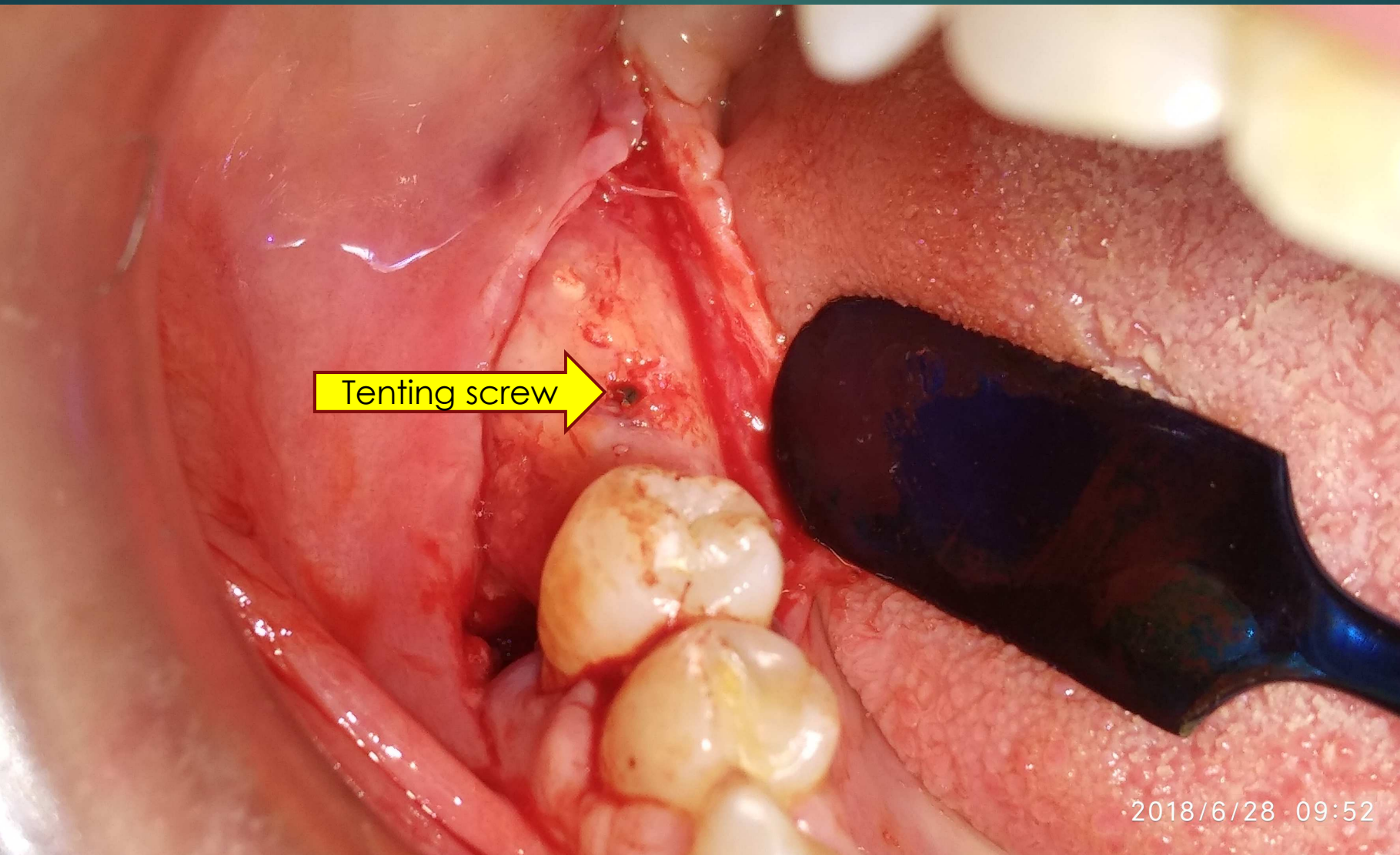


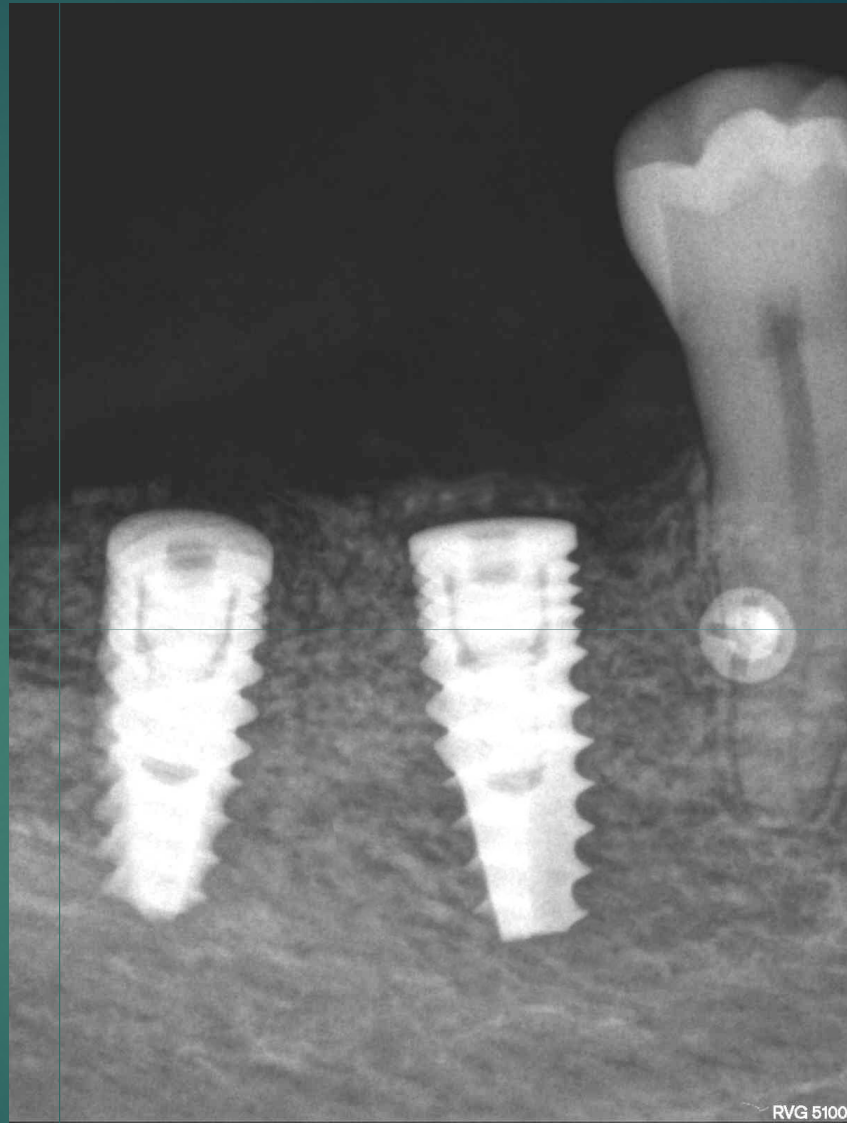
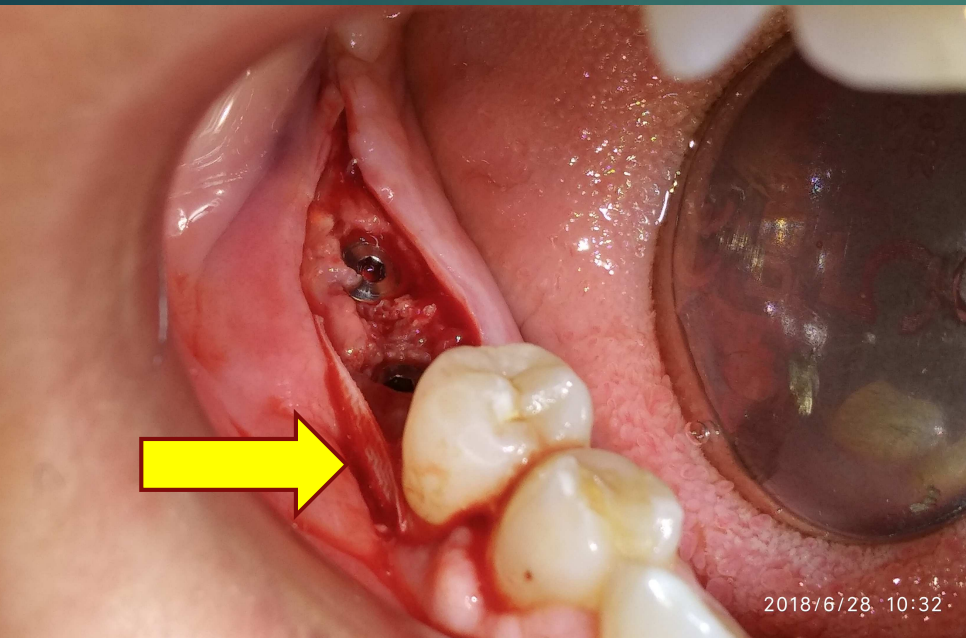
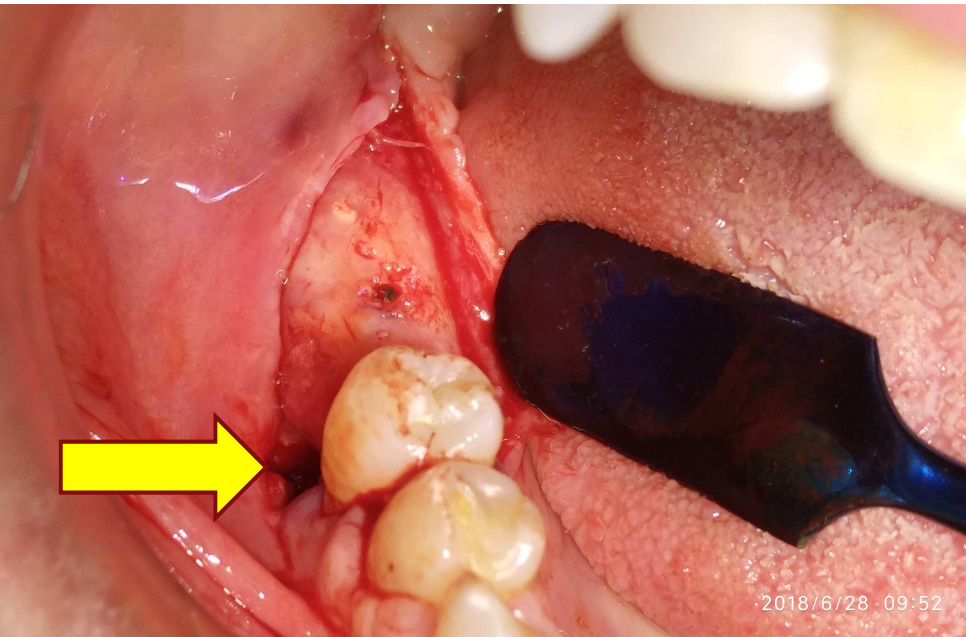
3 mesi

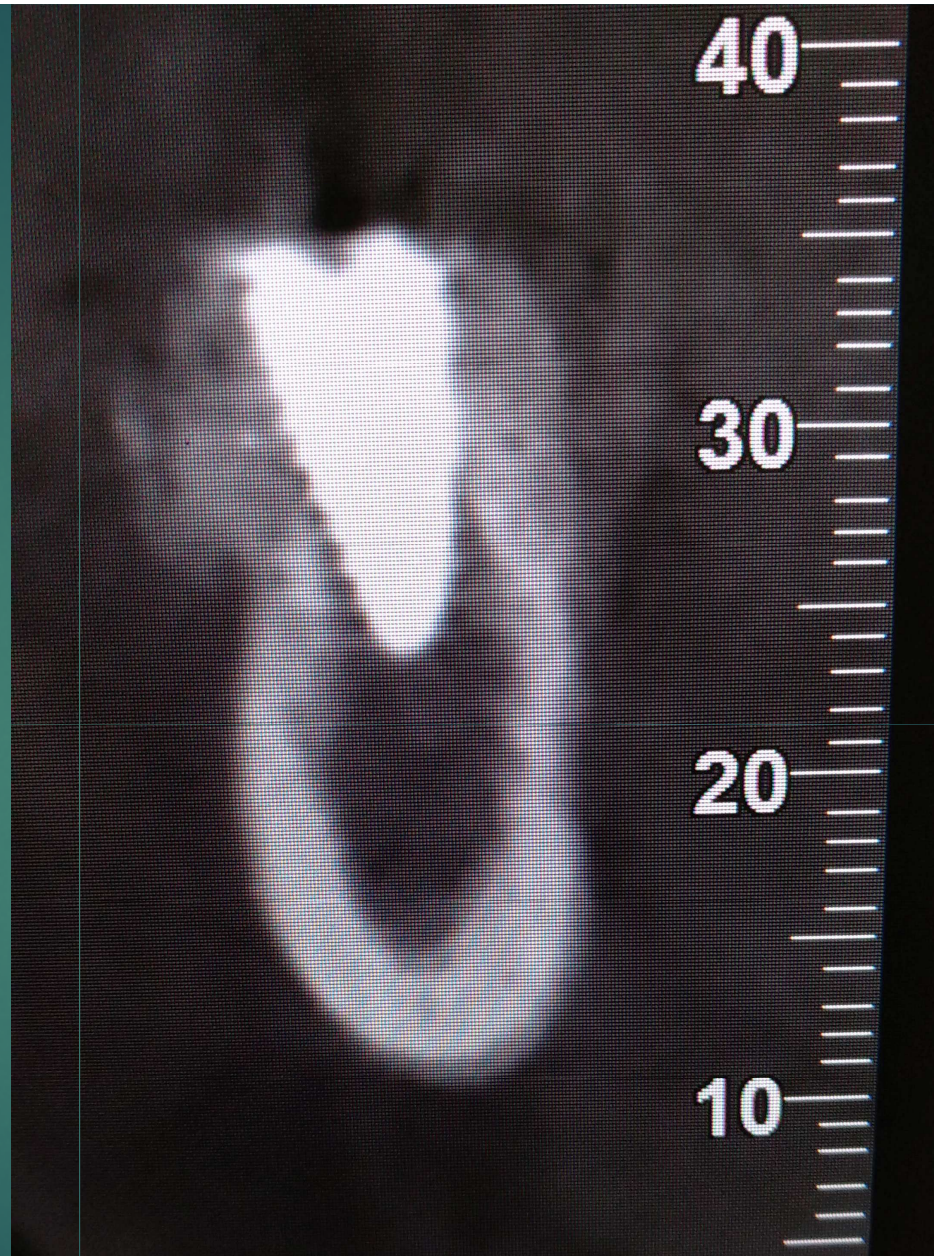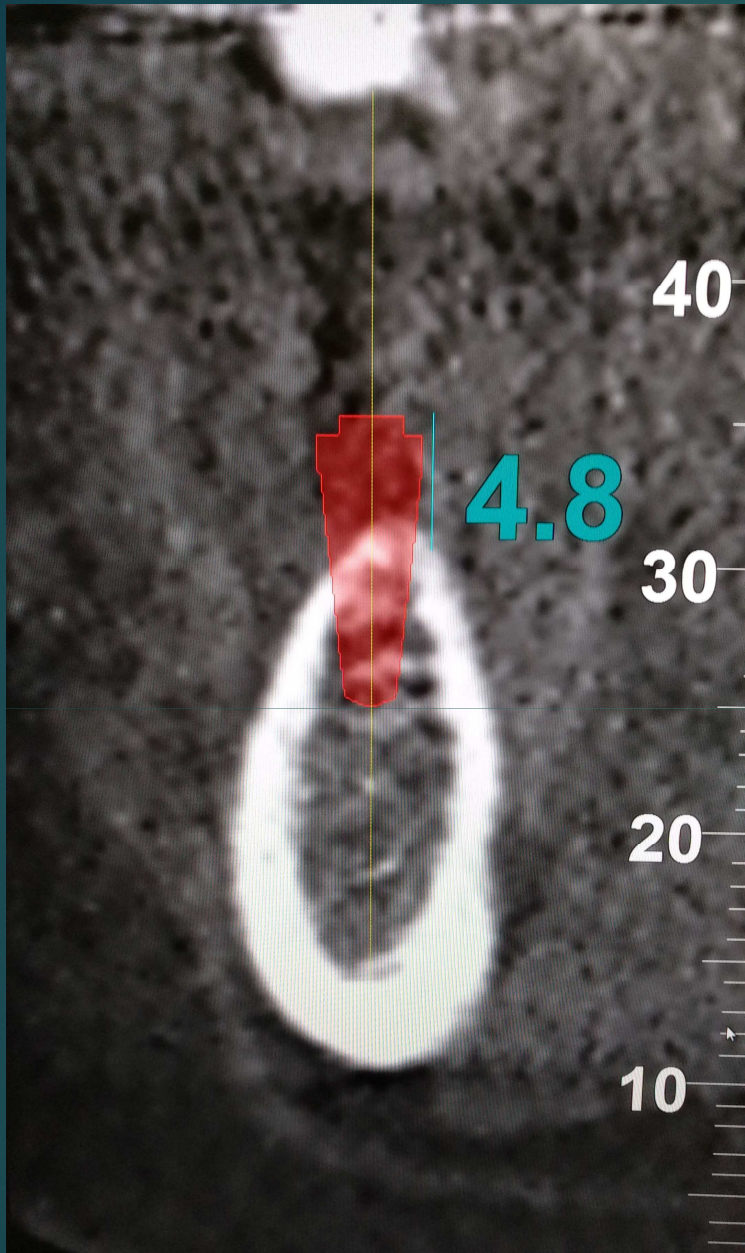


6 mesi

# 1ª Fase Cirúrgica (T6)



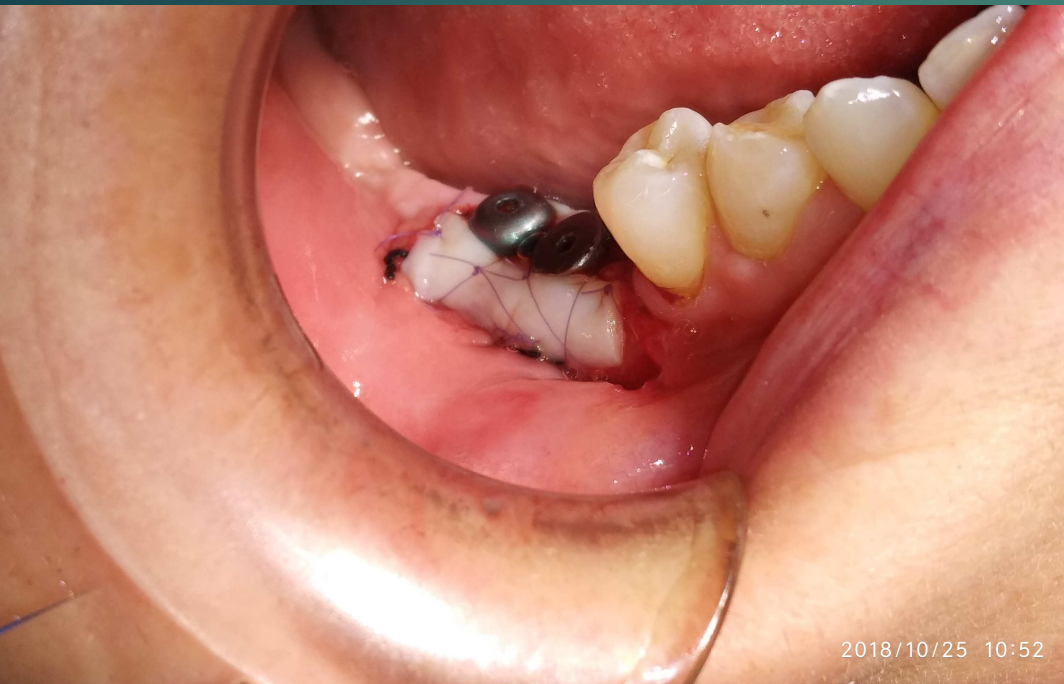



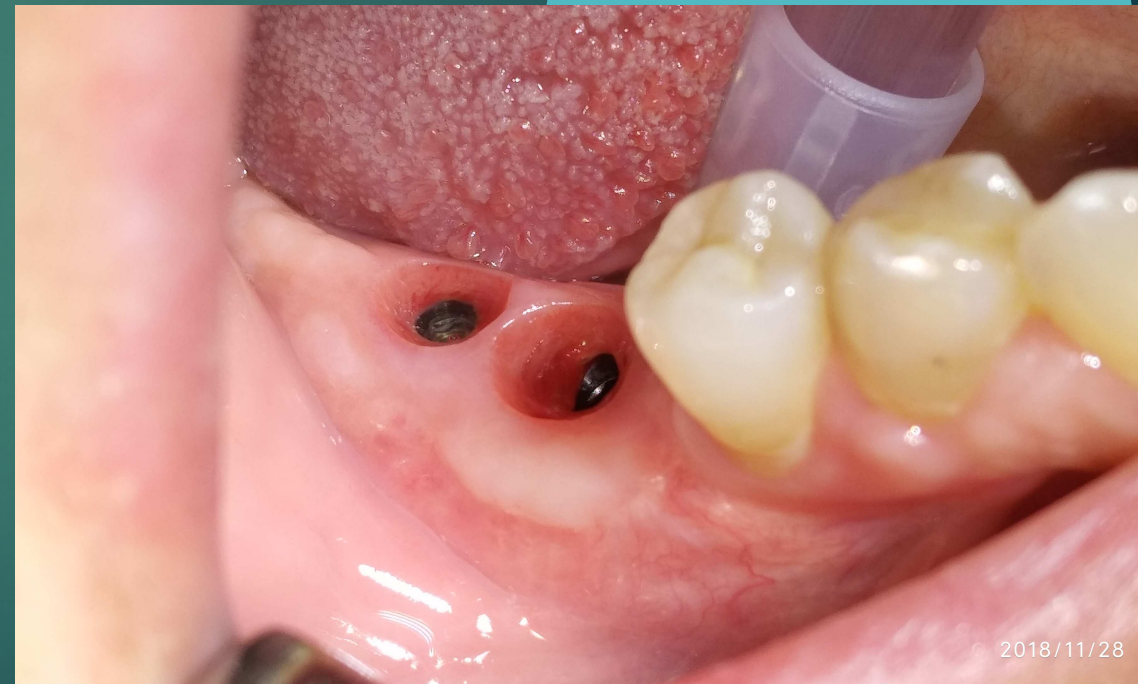# 3° Fase Chirurgica (T9)

19

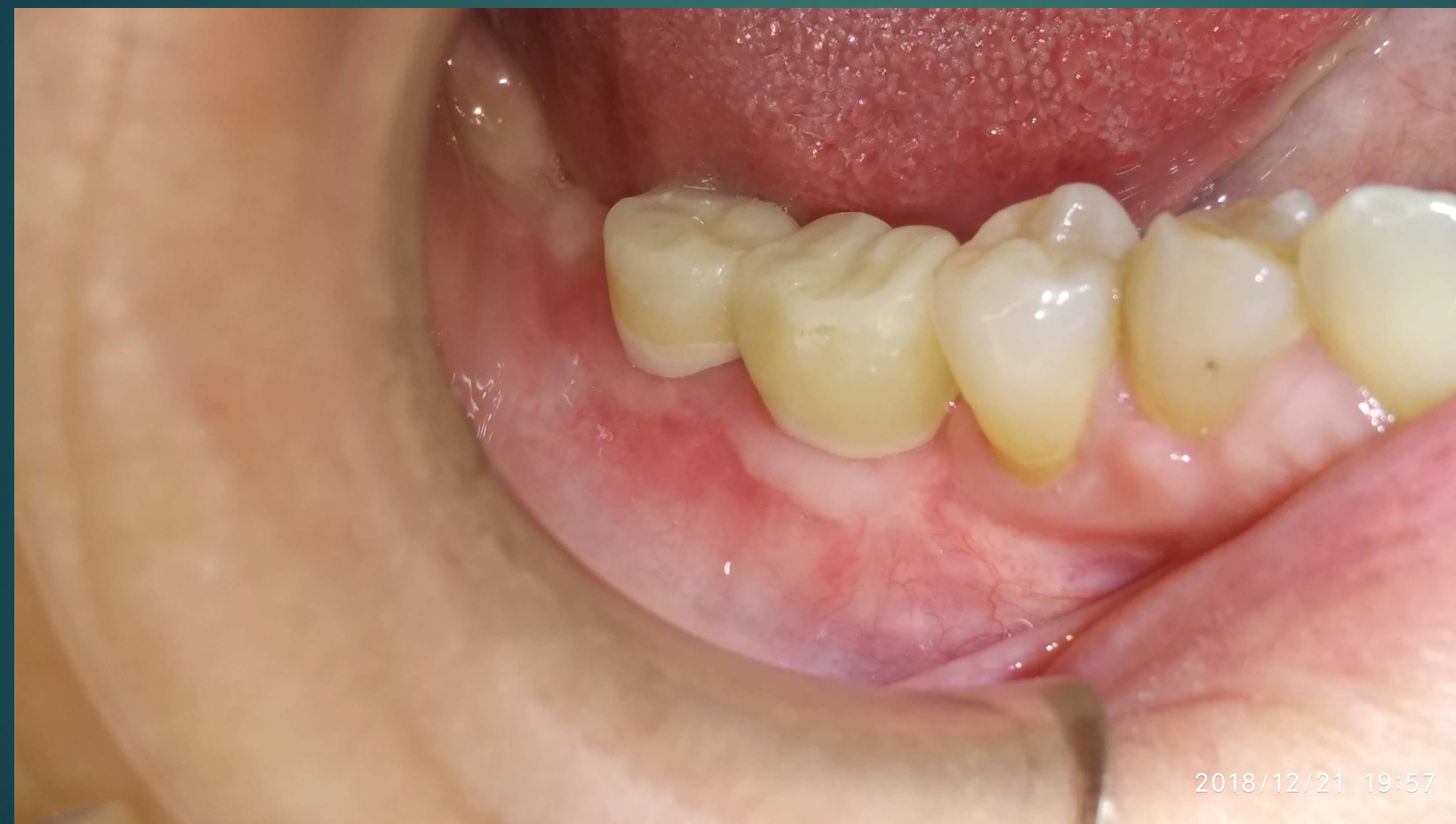Profondimento di fornice, innesto epitelio-  
ectivale e viti di guarigione



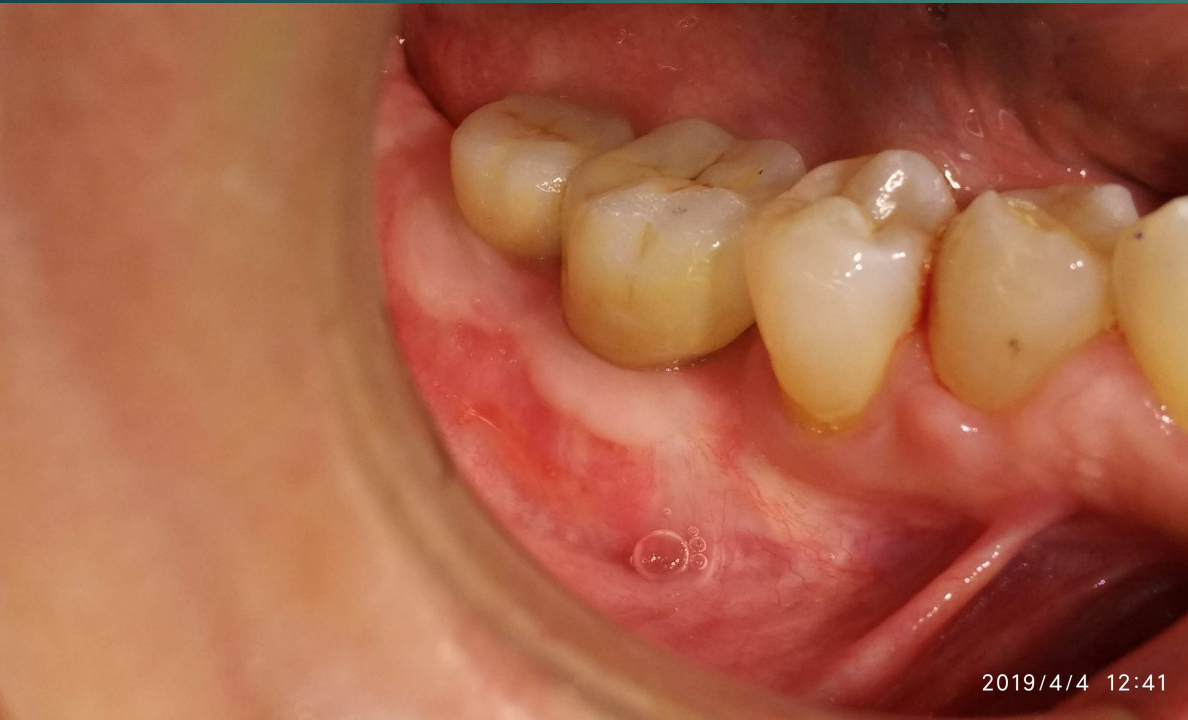Maturazione del tessuto  
cheratinizzato

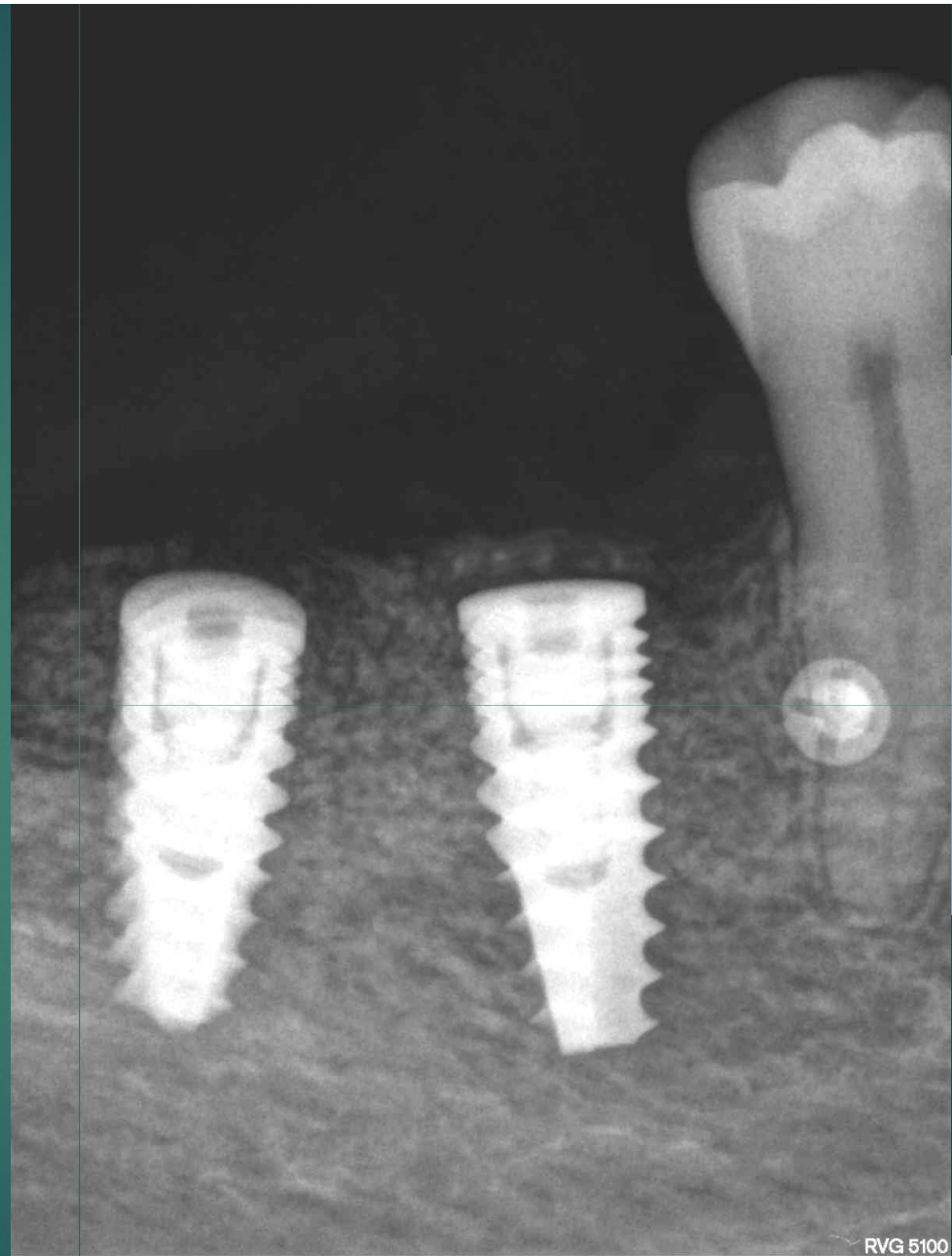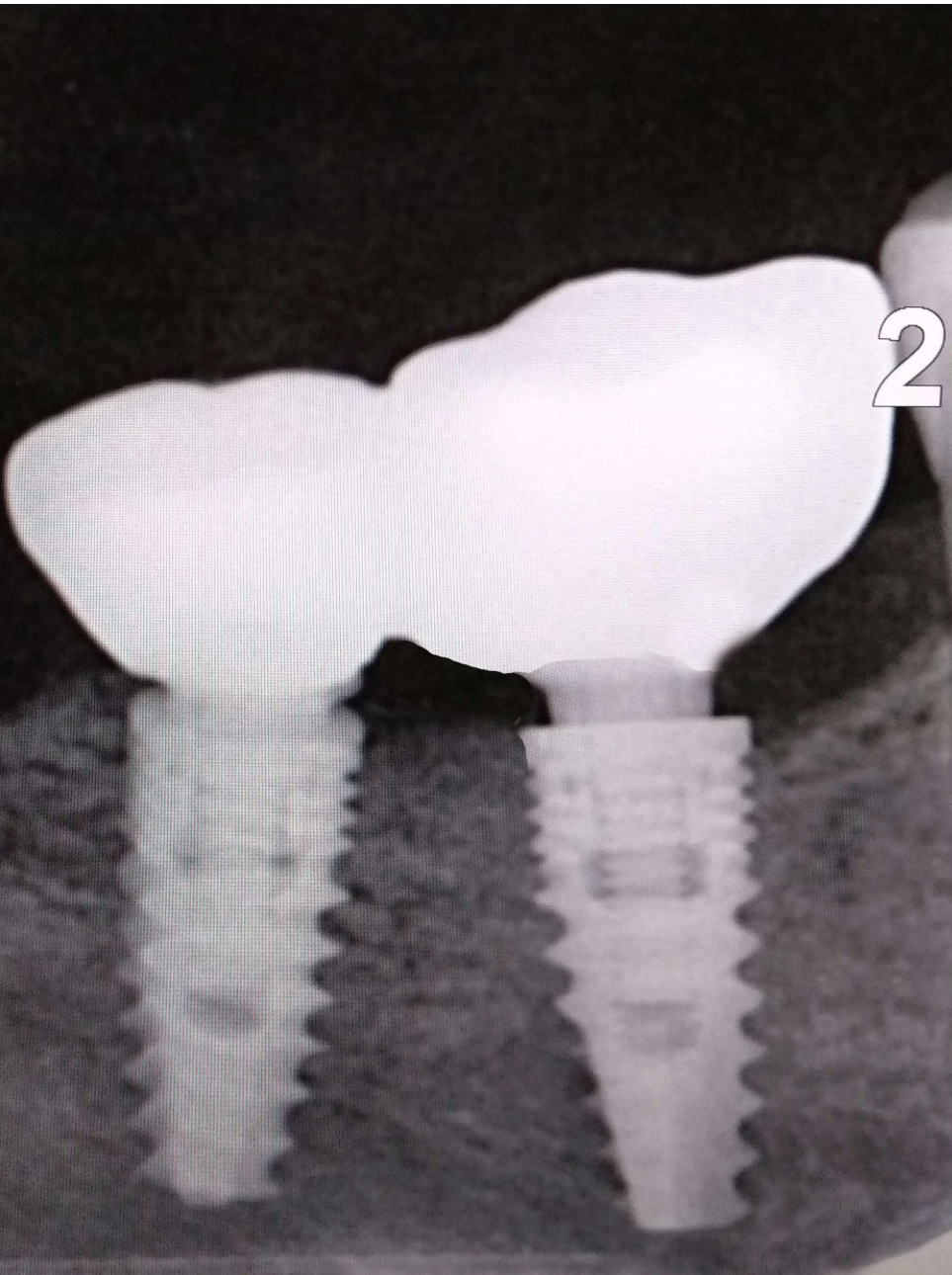


## Protesi provvisoria a carico progressivo



# Protesi definitiva





**Si Ringrazia per la gentile  
concessione il Dott. Mario Torre  
Libero Professionista in Terracina e  
Sabaudia (Latina) ITALY**